



Bronchocutaneous Fistula Secondary to Tuberculosis

✉ Jivtesh Singh¹, ✉ Shruti Vadali², ✉ Prashant Badole¹, ✉ Sanwal Singh Mehta³

¹Department of Internal Medicine, All India Institute of Medical Sciences, Raipur, India

²Department of Internal Medicine, Gomel State Medical University, Gomel, Belarus

³Department of Critical Care Medicine, Jackson Madison County General Hospital, Tennessee, United States of America

A 28-year-old female was referred to the outpatient department for complaints of cough, shortness of breath, and an expansile mass in the upper back and neck that had developed over the previous month. She did not report any comorbidities. The cough had first appeared 4 months ago, and it was associated with yellow sputum, particularly in the morning. Generalized fatigue and shortness of breath developed with mild exertion. Additionally, she experienced undocumented evening fevers that were self-limiting and accompanied by chills and sweating when the fever broke. One month ago, her family noticed a mass between her shoulder blades, which appeared to extend toward her neck and expanded with inhalation (Figure 1a). During this period, the patient also experienced some unintentional weight loss.

On examination, her vital signs were stable. However, the breath sounds and chest expansion were reduced on the upper right side of the chest. An 8 x 2 cm mass was noted between the scapulae, extending toward the neck on the right side. Blood investigations revealed a hemoglobin level of 10 g/dL, a mean corpuscular volume of 88 fL, and an erythrocyte sedimentation rate of 60 mm/h. A chest X-ray revealed a large cavitory lesion in the right lung apex without any pleural fluid collection (Figure 1b). Acid-fast bacilli staining of the patient's sputum yielded a positive result, and the cartridge-based nucleic acid amplification test confirmed the presence of rifampin-sensitive *Mycobacterium tuberculosis*. A chest computed tomography (CT) revealed a large cavitory lesion with air collection extending into the subcutaneous tissue (Figure 1c).

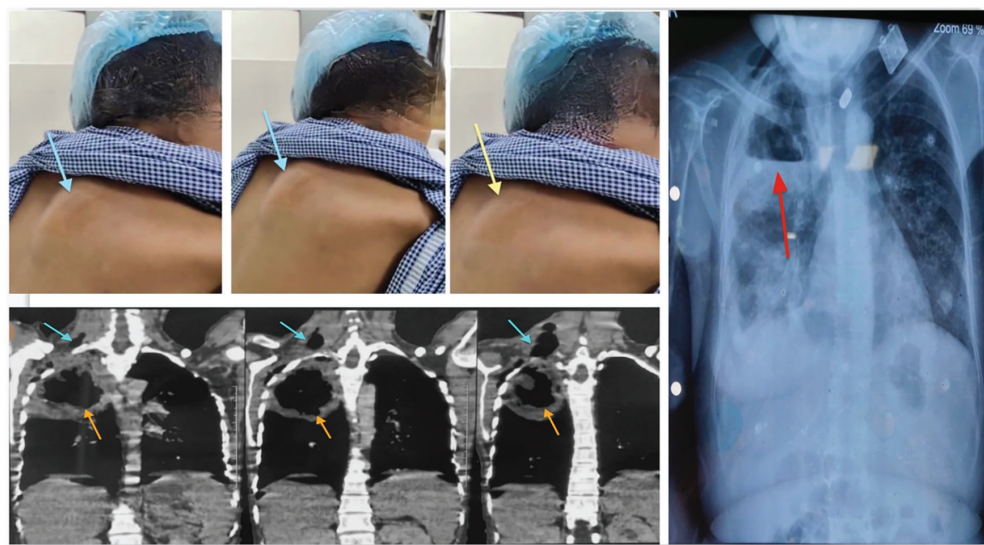


FIG. 1. (a) The blue arrow in the first two frames shows an expansile area during inspiration. The yellow arrow shows the collapse of the same region during expiration. (b) Chest X-ray: the red arrow shows a cavitory lesion in the right upper lobe of the lung. (c) A chest CT revealed an apical cavitory lesion (orange arrows) and a communicating lesion in the subcutaneous plane (blue arrow).

CT, computed tomography.



Corresponding author: Jivtesh Singh, Department of Internal Medicine, All India Institute of Medical Sciences, Raipur, India

e-mail: jivtesh38@gmail.com

Received: October 14, 2024 **Accepted:** November 04, 2024 **Available Online Date:** May 05, 2025 • **DOI:** 10.4274/balkanmedj.galenos.2024.2024-10-56

Available at www.balkanmedicaljournal.org

ORCID iDs of the authors: J.S. 0000-0002-5471-0505; S.V. 0009-0005-0306-3394; P.B. 0009-0001-6105-8973; S.S.M. 0009-0003-9379-4064.

Cite this article as: Singh J, Vadali S, Badole P, Mehta SS. Bronchocutaneous Fistula Secondary to Tuberculosis. *Balkan Med J.* 2025; 42(3):264-5.

Copyright@Author(s) - Available online at <http://balkanmedicaljournal.org/>

The patient was diagnosed with a bronchocutaneous fistula secondary to tuberculosis. A chest tube was inserted, and the standard antitubercular therapy was initiated. Rifampin (600 mg/day), isoniazid (300 mg/day), and ethambutol (1100 mg/day) were administered for 6 months. Pyrazinamide (1600 mg/day) was administered for only 2 months. After a week of minimal drainage, the chest tube was removed, and the patient was discharged. The patient reported improvement in symptoms within a month. After 4 months of treatment, the fistula closed spontaneously, with no residual mass or air collection.

A bronchopleurocutaneous fistula is the formation of an abnormal tract between the bronchus, pleural space, and subcutaneous tissue. It develops following pulmonary surgeries, chest tube placement, perforating trauma to the thorax, pulmonary infections, empyema, and rarely pulmonary infarction.¹ Rarely, aspergillosis, histoplasmosis, and tuberculosis have led to bronchocutaneous fistula formation.²⁻⁴ Usually, such a fistula is formed secondary to empyema necessitans. To the best of our knowledge, our patient appears to be the second reported case of tuberculosis-related bronchocutaneous fistula without any associated empyema.⁵

A bronchocutaneous fistula can be evaluated via imaging studies and bronchoscopic procedures.¹ A thoracic CT is the imaging of choice, and it may reveal new-onset pneumothorax, pneumomediastinum, subcutaneous emphysema, and a fistula between the bronchus and subcutaneous tissue through the chest wall.⁶ Injection of methylene blue into the pleural space and bronchoscopy have been used to delineate the tract of the fistula.⁷ Furthermore, small metallic probes can be introduced via a bronchoscope's channel to evaluate the local site.¹

The management guidelines of the European Institute of Oncology suggest the placement of a chest tube and the administration of broad-spectrum antibiotics in patients with a bronchocutaneous fistula. Further management depends on the fistula size and duration of symptoms. Early postsurgical fistulas (< 14 days) that are < 5 mm can be managed conservatively. Larger fistulas require surgical repair of the bronchial stump. For late postsurgical (> 14

days) and parainfectious fistulas, the first line of management is supportive care. In cases of failure with conservative management, surgical procedures such as completion pneumonectomies, open window thoracostomies, or closure via percutaneous cyanoacrylate glue use can be performed.⁸

Our case report highlights the rare presentation and management of chronic untreated tuberculosis.

Informed Consent: Relevant informed consent was obtained from the patient.

Authorship Contributions: Concept- J.S., P.B., S.S.M.; Supervision- P.B., S.S.M.; Data Collection and/or Processing- S.V.; Analysis and/or Interpretation- S.V.; Literature Search- S.V.; Writing- J.S., S.S.M.; Critical Review- J.S., S.V., P.B., S.S.M.

Conflict of Interest: No conflict of interest was declared by the authors.

REFERENCES

1. Salik I, Vashisht R, Sharma S, Abramowicz AE. Bronchopleural fistula. 2024 Aug 12. In: StatPearls [Internet]. Treasure Island (FL): StatPearls Publishing; 2024. [CrossRef]
2. Johns LE Jr, Garrison RG, White TG. Bronchopleurocutaneous fistula due to infection with *Histoplasma capsulatum*. *Chest*. 1973;63:638-641. [CrossRef]
3. Soto-Hurtado EJ, Marín-Gómez E, Segura-Domínguez N, Jiménez-Oñate F. Pleural aspergillosis with bronchopleurocutaneous fistula and costal bone destruction: a case report. *Lung*. 2005;183:417-423. [CrossRef]
4. Venkatanarayan AN, Unnikrishnan DC, Doraiswamy M, Ghali W. A case of tuberculous bronchopleural fistula managed with open window thoracostomy. *Chest*. 2018;154(Suppl):50A-51A. [CrossRef]
5. Siddiqui MA, Shameem M, Akhtar J, et al. Bronchopleurocutaneous fistula in absence of empyema: a rare presentation of pulmonary tuberculosis. *Lung India*. 2011;28:72-73. [CrossRef]
6. Westcott JL, Volpe JP. Peripheral bronchopleural fistula: CT evaluation in 20 patients with pneumonia, empyema, or postoperative air leak. *Radiology*. 1995;196:175-181. [CrossRef]
7. Hsu JT, Bennett GM, Wolff E. Radiologic assessment of bronchopleural fistula with empyema. *Radiology*. 1972;103:41-45. [CrossRef]
8. Mazzella A, Casiraghi M, Uslenghi C, et al. Bronchopleural fistula after lobectomy for lung cancer: how to manage this life-threatening complication using both old and innovative solutions. *Cancers (Basel)*. 2024;16:1146. [CrossRef]