



Cystic Bronchiectasis due to AIDS: Case and References

Songyang Pan¹, Miao Chen², Tianyang Dai¹

¹Department of Thoracic Surgery, The Affiliated Hospital of Southwest Medical University, Luzhou, China

²Department of Respiratory Medicine, People's Hospital of Leshan, Leshan, China

A 31-year-old man presented to the hospital with a 10-month history of chronic dry cough and progressive dyspnea. He reported a 3-year history of recurrent Pneumocystis pneumonia. He had been diagnosed with human immunodeficiency virus (HIV) infection 1 year earlier but had not received antiretroviral therapy. On admission, bilateral lung auscultation revealed crackles, and oxygen saturation was 90%. Pulmonary function tests showed a mild obstructive ventilatory defect and small airway dysfunction. Laboratory results included a white blood cell count of 1390/mm³ (reference range, 3500-9500), a lymphocyte count of 300/mm³ (reference range, 1100-3200), and a CD4/CD8 ratio of 0.07 (reference range, 0.71-2.87). Chest radiography demonstrated extensive, multiple, large, coalescent cystic bronchiectasis and a left pneumothorax (5%) (Figure 1a). Computed tomography (CT) of the chest revealed multiple cystic dilations of the segmental bronchi (4th-6th order) (Figures 1b-d). After 2 weeks of nebulized antibiotics and sulfamethoxazole treatment, the patient's symptoms resolved. However, at the 1-year follow-up, he was repeatedly hospitalized for pulmonary infections.

Pneumocystis pneumonia is the most common opportunistic infection in patients with acquired immunodeficiency syndrome (AIDS).¹ This case highlights the severe pulmonary sequelae of untreated HIV infection and recurrent opportunistic infections, particularly Pneumocystis pneumonia.

The patient developed advanced complications, including extensive cystic bronchiectasis, resulting from profound immunosuppression and a history of multiple Pneumocystis pneumonia episodes over the 3 years preceding his HIV diagnosis. Critically, the lack of antiretroviral therapy during the year following diagnosis allowed unchecked viral replication and immune deterioration, predisposing him to recurrent opportunistic infections and end-organ damage.

The development of extensive cystic bronchiectasis is a central finding in this case. While Pneumocystis pneumonia is the most common AIDS-defining opportunistic infection, recurrent episodes are a significant

risk factor for irreversible lung damage. The pathophysiological mechanism likely involves recurrent inflammatory insults that weaken the bronchial walls, combined with impaired clearance due to immunodeficiency, ultimately leading to bronchial dilation and cyst formation², as vividly demonstrated on CT. Fujishima et al.³ also reported a case of Pneumocystis pneumonia complicated by bronchiectasis, suggesting a strong inflammatory component.

These cases align with emerging evidence that bronchiectasis is becoming an increasingly recognized long-term complication in people living with HIV, particularly those with a history of severe or recurrent pulmonary infections such as Pneumocystis pneumonia.⁴ The structural lung damage predisposes patients to a vicious cycle of recurrent bacterial respiratory infections, as seen in this patient's repeated hospitalizations.

Management highlights include the patient's transient symptomatic improvement with targeted treatment-antibiotics for presumed bacterial superinfection and sulfamethoxazole for Pneumocystis pneumonia prophylaxis/treatment.⁵ However, the recurrent infections at 1-year follow-up underscore the importance of addressing the underlying cause: uncontrolled HIV infection.

Antiretroviral therapy remains the cornerstone of management, as it promotes immune reconstitution, prevents further opportunistic infections, and may halt the progression of HIV-associated lung diseases such as bronchiectasis. This case strongly emphasizes the critical importance of early HIV diagnosis, prompt initiation of antiretroviral therapy, and rigorous adherence to prevent devastating and potentially irreversible pulmonary complications.

While prophylaxis against Pneumocystis pneumonia remains essential in severely immunocompromised patients, preventing immunosuppression through timely antiretroviral therapy is the ultimate goal.

Corresponding author: Tianyang Dai, Department of Thoracic Surgery, The Affiliated Hospital of Southwest Medical University, Luzhou, China

e-mail: daitianyang0520@sina.com

Received: August 13, 2025 **Accepted:** September 02, 2025 **Available Online Date:** April 1, 2026 • **DOI:** 10.4274/balkanmedj.galenos.2025.2025-8-80

Available at www.balkanmedicaljournal.org

ORCID iDs of the authors: S.P. 0009-0006-3983-0636; M.C. 0009-0008-3887-5204; T.D. 0009-0000-5812-7950.

Cite this article as: Pan S, Chen M, Dai T. Cystic Bronchiectasis due to AIDS: Case and References. *Balkan Med J*. 2026;43:212-213

Copyright@Author(s) - Available online at <http://balkanmedicaljournal.org/>

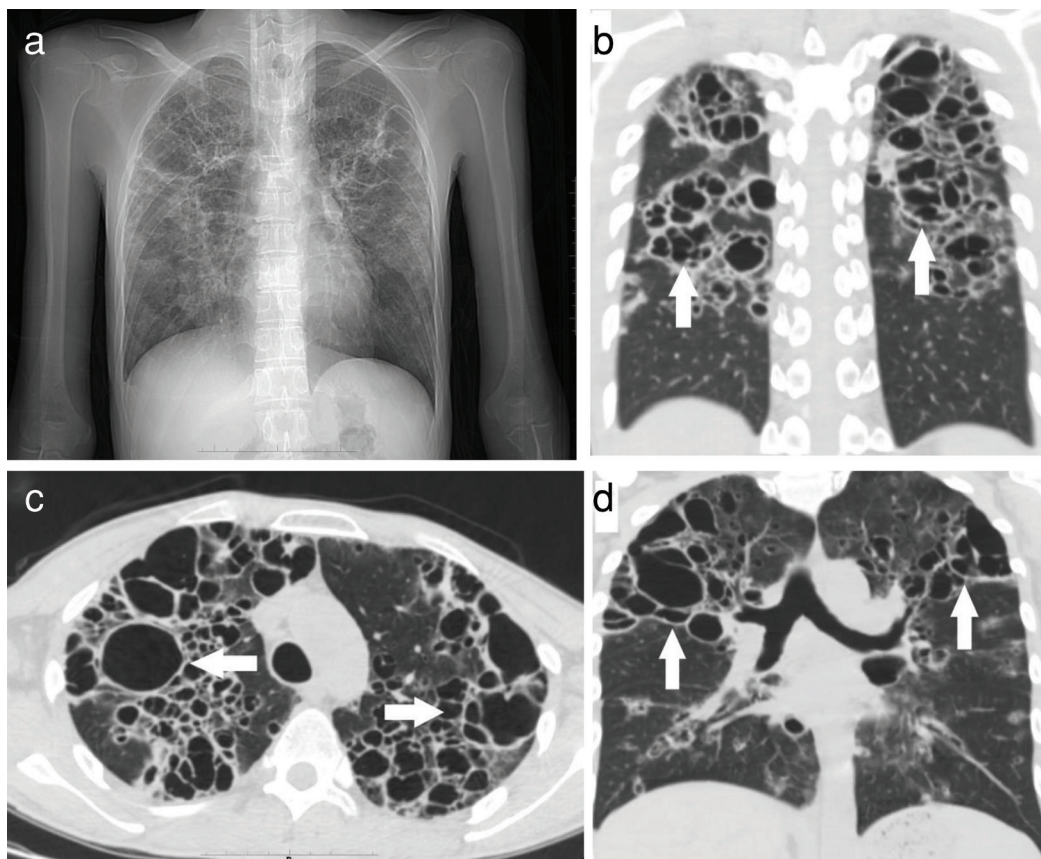


FIG. 1. X-ray and CT manifestations of bronchiectasis.

CT, computed tomography.

Acknowledgements: We are grateful to Prof. Zhi Hu, and the members of the Department of Thoracic Surgery, for their generous help.

Informed Consent: This article has obtained informed consent from the patient.

Authorship Contributions: Conception- T.D.; Writing- S.P., M.C.; Critical Review- T.D.

Conflict of Interest: No conflict of interest was declared by the authors.

REFERENCES

1. Thomas CF Jr, Limper AH. Pneumocystis pneumonia. *N Engl J Med.* 2004;350:2487-2498. [\[CrossRef\]](#)
2. Clausen E, Wittman C, Gingo M, et al. Chest computed tomography findings in HIV-infected individuals in the era of antiretroviral therapy. *PLoS One.* 2014;9:e112237. [\[CrossRef\]](#)
3. Fujishima N, Hioki Y, Yokoyama A, Hiramatsu K, Komiya K. Pneumocystis pneumonia presenting with peripheral predominant consolidation and traction bronchiectasis. *Cureus.* 2024;16:e63257. [\[CrossRef\]](#)
4. Boettiger DC, An VT, Lumbiganon P, et al. TREAT Asia pediatric HIV observational database. severe recurrent bacterial pneumonia among children living with HIV. *Pediatr Infect Dis J.* 2022;41:e208-e215. [\[CrossRef\]](#)
5. Weyant RB, Kabbani D, Doucette K, Lau C, Cervera C. Pneumocystis jirovecii: a review with a focus on prevention and treatment. *Expert Opin Pharmacother.* 2021;22:1579-1592. [\[CrossRef\]](#)