



# Occult Childhood Interstitial Lung Disease

● Zhong-Qiang Li, ● Xue-Jun Wu

Department of Pediatrics, Linyi People's Hospital, Linyi, China

A 3-year-old girl was admitted with a 2-day history of nasal congestion and cough, accompanied by wheezing for 1 day. She had no dyspnea or cyanosis. She was born by cesarean section at 32 + 3 weeks of gestation because of placenta previa, with a birth weight of 1.85 kg. Shortly after birth, she developed grunting and cyanosis and was diagnosed with neonatal respiratory distress syndrome (RDS). She required non-invasive continuous positive airway pressure ventilation for 53 hours, followed by low-flow nasal cannula oxygen therapy for 20 days, after which she was discharged upon symptom resolution.

After discharge, she demonstrated normal activity tolerance and did not exhibit chronic cough, recurrent wheezing, or other respiratory symptoms. At presentation, her weight was 12 kg (3<sup>rd</sup>–10<sup>th</sup> percentile for age), and her height was 95 cm (25<sup>th</sup>–50<sup>th</sup> percentile). Physical examination revealed a thin-built child with a heart rate of 140 beats/min and a respiratory rate of 42 breaths/min. No intercostal retractions were noted. The inspiratory-to-expiratory ratio was 0.69. Auscultation revealed bilateral wheezing and fine crackles.

Laboratory evaluation showed an oxygen saturation of 96% on room air and an elevated C-reactive protein level of 11.5 mg/L. A nasopharyngeal swab for respiratory pathogen DNA was positive for human rhinovirus. There was no family history of genetic disease.

Given the patient's history of prematurity complicated by RDS, evidence of failure to thrive, and persistent tachypnea, chest computed tomography (CT) was performed to evaluate pulmonary anatomy and exclude underlying conditions such as airway or lung malformations and foreign body aspiration. Unexpectedly, CT imaging revealed multiple subpleural honeycombing patterns in both lungs, with heterogeneous lung attenuation. In addition, small nodules and linear opacities were observed in the right lung (Figures 1a-d). These radiologic findings were highly suggestive of childhood interstitial lung disease (chILD). Following admission, the patient received low-flow oxygen therapy for 16 hours.

Concurrently, the patient was treated with nebulized budesonide suspension and terbutaline solution twice daily. Her tachypnea resolved by the second hospital day. After a 5-day hospital stay, she was discharged with complete resolution of cough and wheezing.

Follow-up assessments at 2, 6, and 9 months post-discharge revealed no recurrent respiratory symptoms. Oxygen saturation remained within normal limits both at rest and during physical activity.

chILD comprises a rare and heterogeneous group of parenchymal lung disorders characterized by impaired gas exchange and diffuse radiologic abnormalities.<sup>1</sup> The distinctive feature of the present case is that chILD was identified incidentally during an episode of acute viral respiratory infection, whereas the underlying chronic lung pathology had remained unrecognized because of the absence of persistent respiratory symptoms.

The patient had a clear history of prematurity and neonatal RDS, both of which are considered risk factors for abnormal lung development. Prematurity may result in alveolar dysplasia or disrupted alveolar growth,<sup>2</sup> and when combined with RDS—characterized by surfactant deficiency<sup>3</sup>—these factors may contribute to the development of chILD. With advances in perinatal care, survival rates of extremely preterm infants have improved; however, bronchopulmonary dysplasia (BPD) and its long-term pulmonary sequelae have emerged as significant clinical concerns.<sup>4</sup> The pathological features of BPD primarily include lung injury, impaired alveolarization, and varying degrees of fibrosis.<sup>5</sup>

Although this patient did not meet the conventional diagnostic criteria for BPD during the neonatal period—defined as oxygen dependence for more than 28 days—the early exposure to mechanical ventilation and supplemental oxygen may still have caused injury to immature lung tissue. Such injury can disrupt normal alveolar development and lead to microstructural abnormalities resembling those seen in prematurity-associated interstitial lung disease.<sup>6</sup> The subpleural honeycombing and heterogeneous lung lucency observed on chest CT are characteristic of pulmonary fibrosis and architectural distortion.<sup>7</sup>

Human rhinovirus infection likely served as the trigger for this acute episode, which often causes severe lower respiratory tract symptoms, including wheezing and ventilatory dysfunction, particularly in children with underlying lung disease. The patient was followed for 9 months after symptom improvement, who showed no clinical symptoms, thereby was indicative of disease quiescence rather than



**Corresponding author:** Xue-Jun Wu, Department of Pediatrics, Linyi People's Hospital, Linyi, China

**e-mail:** wxj9759@163.com

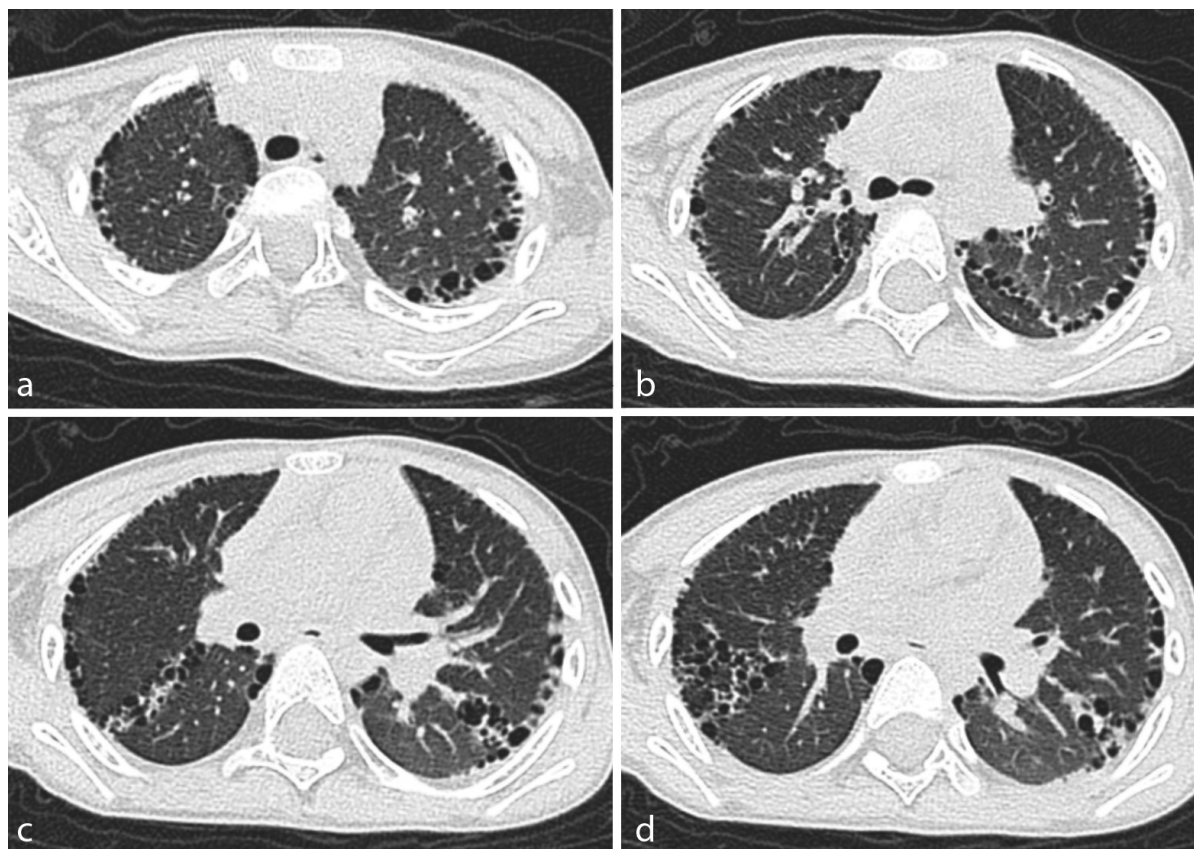
**Received:** December 02, 2025 **Accepted:** December 14, 2025 • **DOI:** 10.4274/balkanmedj.galenos.2025.2025-11-274

Available at [www.balkanmedicaljournal.org](http://www.balkanmedicaljournal.org)

**ORCID iDs of the authors:** Z.Q.L. 0009-0000-1023-2620; X.J.W. 0009-0006-1424-4411.

**Cite this article as:** Li ZQ, Wu XJ. Occult Childhood Interstitial Lung Disease. *Balkan Med J*;

Copyright@Author(s) - Available online at <http://balkanmedicaljournal.org/>



**FIG. 1.** (a-d) Axial chest computed tomography images demonstrate bilateral subpleural cystic changes consistent with honeycombing, along with heterogeneous lung attenuation.

resolution of the pathology. Notably, repeat chest CT imaging was declined by the guardian during follow-up, although a surveillance CT scan was recommended 12 months after discharge.

Establishing the etiology of chILD is essential for prognostication and management. Genetic testing and lung biopsy are considered diagnostic cornerstones and may guide individualized treatment strategies.<sup>8</sup> However, in this case, the guardians declined further invasive investigations and genetic evaluation, introducing uncertainty regarding long-term disease progression and management. This case highlights an important clinical lesson; children with a history of prematurity, particularly those complicated by neonatal RDS. In such cases, despite their normal clinical presentation during infancy and early childhood, there might exist occult, persistent structural damage in the lungs.

**Informed Consent:** Written informed consent for the publication of the clinical images was obtained from the patient's family.

**Authorship Contributions:** Design- Z.Q.L.; Funding- X.J.W., Z.Q.L.; Materials- X.J.W.; Writing- Z.Q.

**Funding:** This work was supported by the Key Research and Development Program of Linyi City (Medical Category) (Project No: 2024YX0011).

**Conflict of Interest:** No conflict of interest was declared by the authors.

## REFERENCES

1. Nayir Buyuksahin H, Kiper N. Childhood interstitial lung disease. *Pediatr Allergy Immunol Pulmonol.* 2023;36:5-15. [\[CrossRef\]](#)
2. Tsujioka Y, Nishimura G, Nishi E, et al. Childhood interstitial lung diseases: current understanding of the classification and imaging findings. *Jpn J Radiol.* 2024;42:937-952. [\[CrossRef\]](#)
3. Marczak H, Krenke K, Griesse M, et al; ERS CRC chILD-EU group. An update on diagnosis and treatments of childhood interstitial lung diseases. *Breathe (Sheff).* 2025;21:250004. [\[CrossRef\]](#)
4. Obst S, Herz J, Alejandre Alcazar MA, et al. Perinatal hyperoxia and developmental consequences on the lung-brain axis. *Oxid Med Cell Longev.* 2022;2022:5784146. [\[CrossRef\]](#)
5. Callaway DA, Wang Y, Lingappan K, et al. Lung biopsy in infants with severe bronchopulmonary dysplasia. *Pediatr Pulmonol.* 2023;58:2068-2075. [\[CrossRef\]](#)
6. Ding KL, Smith C, Seedorf G, Abman SH. Nintedanib preserves lung growth and prevents pulmonary hypertension in a hyperoxia-induced lung injury model. *Pediatr Res.* 2025;97:1676-1683. [\[CrossRef\]](#)
7. Nathan N, Griesse M, Michel K, et al; ERS CRC chILD-EU group. Diagnostic workup of childhood interstitial lung disease. *Eur Respir Rev.* 2023;32:220188. [\[CrossRef\]](#)
8. Kurland G, Deterding RR, Hagood JS, et al; American Thoracic Society Committee on Childhood Interstitial Lung Disease (chILD) and the chILD Research Network. An official American Thoracic Society clinical practice guideline: classification, evaluation, and management of childhood interstitial lung disease in infancy. *Am J Respir Crit Care Med.* 2013;188:376-394. [\[CrossRef\]](#)