



# Onychopapilloma and Ungual Fibroma Revealing Late-Diagnosed Tuberous Sclerosis

Buğra Burç Dağtaş<sup>1</sup>, Cem Leblebici<sup>2</sup>

<sup>1</sup>Clinic of Dermatology, University of Health Sciences Türkiye, İstanbul Training and Research Hospital, İstanbul, Türkiye

<sup>2</sup>Clinic of Pathology, University of Health Sciences Türkiye, İstanbul Training and Research Hospital, İstanbul, Türkiye

A 75-year-old woman with a known history of diabetes mellitus and hypertension presented with a long-standing deformity of the right third fingernail. On examination, a distinct longitudinal erythroxanthonychia with an irregular distal subungual keratotic mass was noted (Figures 1a, b). Dermoscopy further characterized the lesion, showing a clearly defined distal hyperkeratotic mass and a 3-mm longitudinal band running from the proximal nail fold to the hyponychium-an identifying feature of onychopapilloma (Figure 1c).<sup>1,2</sup> Based on these findings, surgical excision was planned.

During surgery, in addition to the distal lesion, a firm, well-defined subcutaneous nodule (~8 mm) was found at the proximal nail fold and was also excised (Figure 1d). Histopathological examination of the distal specimen showed marked acanthosis with focal papillomatosis and layered subungual hyperkeratosis, confirming onychopapilloma (Figure 1e). In contrast, the proximal specimen revealed thick collagen bundles arranged in a loose storiform pattern, consistent with ungual fibroma (Figure 1f).<sup>3</sup> Immunohistochemistry showed diffuse CD34 positivity in the ungual fibroma, while the onychopapilloma was CD34-negative.

After surgery, a thorough total-body skin examination was conducted, which revealed multiple, longstanding facial papules and toenail lesions highly suggestive of periungual fibromas (Figures 2a-c). Biopsy of a facial papule showed an epidermis-covered polypoid lesion consisting of irregular connective tissue proliferation with increased vascularity, consistent with angiofibroma (Figure 2d). Both angiofibromas and ungual fibromas are major diagnostic criteria for

tuberous sclerosis complex (TSC).<sup>4</sup> Notably, there are no prior reports linking onychopapilloma with TSC. In this patient, the presence of two major diagnostic criteria raised strong suspicion for TSC, and subsequent genetic testing confirmed a pathogenic *TSC1* gene mutation, establishing the diagnosis. Written informed consent was obtained from the patient to publish this case details and the related images.

Diagnosed with TSC at the age of 75 years, the patient was placed under regular follow-up and referred for a multidisciplinary evaluation to assess possible systemic involvement. To our knowledge, coexistence of onychopapilloma and TSC has not been previously reported in the medical literature, so their concurrence in this patient is considered coincidental rather than causal. Nonetheless, this report broadens the clinical spectrum of nail tumors by documenting this coexistence for the first time. This case highlights the diagnostic value of a detailed nail unit evaluation and shows how an isolated nail finding can be a critical clue for identifying systemic genodermatoses. Combining clinical, dermoscopic, histopathologic, and genetic information is vital for recognizing such complex presentations, ultimately supporting earlier and more accurate diagnoses.

**Informed Consent:** Written informed consent was obtained from the patient to publish this case details and the related images.

**Authorship Contributions:** Concept- B.B.D.; Data Collection or Processing- C.L.; Literature Review- C.L.; Writing- B.B.D., C.L.

**Conflict of Interest:** No conflict of interest was declared by the authors.



**Corresponding author:** Buğra Burç Dağtaş, Clinic of Dermatology, University of Health Sciences Türkiye, İstanbul Training and Research Hospital, İstanbul, Türkiye

**e-mail:** bugradagtas@gmail.com

**Received:** April 07, 2025 **Accepted:** May 24, 2025 **Available Online Date:** • **DOI:** 10.4274/balkanmedj.galenos.2025-4-16

Available at [www.balkanmedicaljournal.org](http://www.balkanmedicaljournal.org)

**ORCID iDs of the authors:** B.B.D. 0000-0002-9592-9968; C.L. 0000-0003-4964-1741.

**Cite this article as:** Dağtaş BB, Leblebici C. Onychopapilloma and Ungual Fibroma Revealing Late-Diagnosed Tuberous Sclerosis. *Balkan Med J*;

Copyright@Author(s) - Available online at <http://balkanmedicaljournal.org/>

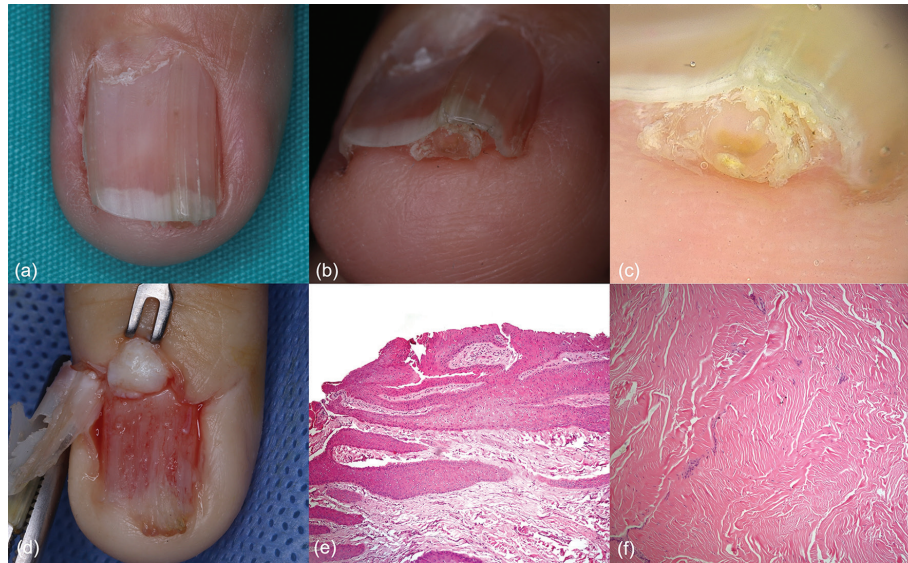

FIG.1. (a) Longitudinal erythroxanthonychia and asymmetric elevation of the nail plate on the right third fingernail. A firm, fixed subcutaneous nodule (~8 mm) is visible beneath the proximal nail fold, with medial depression and lateral elevation. (b) Clinical close-up showing a subungual hyperkeratotic mass (~5 mm) beneath the distal free edge of the nail. (c) Dermoscopy reveals a well-circumscribed distal subungual hyperkeratotic mass, a hallmark feature of onychopapilloma. (d) Intraoperative view following wing block and matrix anesthesia, showing avulsed nail plate and excised proximal mass along with a longitudinal band extending toward the distal hyperkeratotic lesion. (e) Histopathology of the distal nail bed lesion revealing acanthosis and focal papillomatosis of stratified squamous epithelium, consistent with onychopapilloma (H&E,  $\times 200$ ). (f) Histopathology of the proximal lesion demonstrating thick collagen bundles forming a loose storiform pattern, consistent with ungual fibroma (H&E,  $\times 400$ ).

H&E, hematoxylin and eosin.

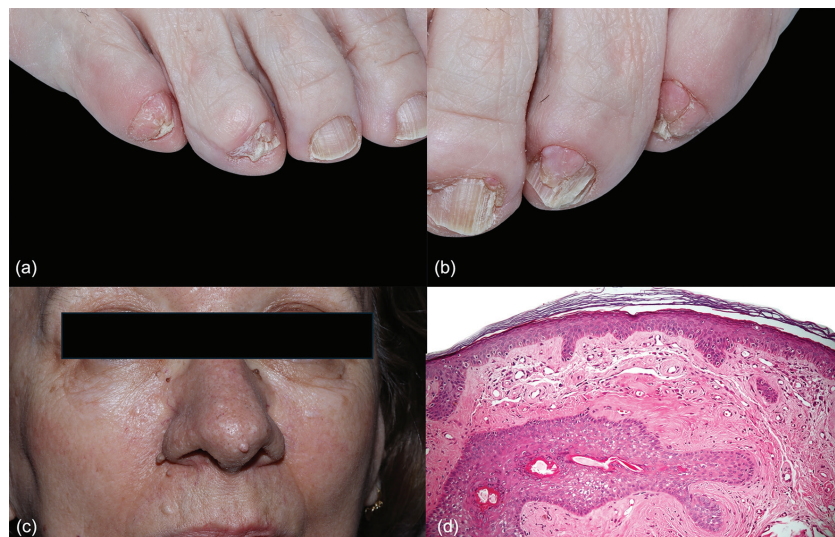


FIG. 2. (a, b) Clinical images showing multiple periungual fibroma-like lesions affecting several toenails of both feet, totaling five lesions. (c) Multiple long-standing papules, each measuring a few millimeters, distributed over the patient's face, clinically consistent with angiofibromas. (d) Histopathological examination of a facial papule biopsy showing an epidermal-covered polypoid lesion characterized by irregular connective tissue proliferation and increased vascularity, consistent with angiofibroma (H&E,  $\times 200$ ).

H&E, hematoxylin and eosin.

## REFERENCES

1. Tosti A, Schneider SL, Ramirez-Quizon MN, Zaiac M, Miteva M. Clinical, dermoscopic, and pathologic features of onychopapilloma: a review of 47 cases. *J Am Acad Dermatol.* 2016;74:521-526. [\[CrossRef\]](#)
2. Richert B, Lecerf P, Caucanas M, André J. Nail tumors. *Clin Dermatol.* 2013;31:602-617. [\[CrossRef\]](#)
3. Ma D, Darling T, Moss J, Lee CC. Histologic variants of periungual fibromas in tuberous sclerosis complex. *J Am Acad Dermatol.* 2011;64:442-444. [\[CrossRef\]](#)
4. Aldrich CS, Hong CH, Groves L, Olsen C, Moss J, Darling TN. Acral lesions in tuberous sclerosis complex: insights into pathogenesis. *J Am Acad Dermatol.* 2010;63:244-251. [\[CrossRef\]](#)