

Case Report / *Olgu Sunumu*

## Extra-Abdominal Aggressive Fibromatosis Presenting As an Intrathoracic Tumor

### *Intratorasik Ekstra Abdominal Agresif Fibromatozis*

Yener YÖRÜK, Yekta Altumur KARAMUSTAFAOĞLU, Yavuz Atakan SEZER<sup>1</sup>, Abdil Cem İBİŞ<sup>1</sup>

*Departments of Thoracic Surgery and General Surgery<sup>1</sup>, Medical Faculty of Trakya University, Edirne*

**Submitted / Başvuru tarihi:** 06.08.2008 **Accepted / Kabul tarihi:** 26.10.2008

Tumors of fibrous tissue origin (fibromatosis) in chest and mediastinum have been rarely reported in the literature. Herein, we report a rare case of aggressive fibromatosis presenting as an intrathoracic tumor. A 36-year-old woman admitted to our hospital due to a feeling of oppression and pain in the left chest. A chest X-ray, thorax computed tomography revealed a large mass filling two thirds of lower left thorax. Widely surgical resection of the tumor was performed thoracotomy via seventh intercostal space. The tumor was 20x15x15 mm in size and diagnosed pathologically as aggressive fibromatosis. The patient has been well without recurrence for 15 months after surgery.

**Key words:** Aggressive fibromatosis; desmoid tumor.

Fibröz doku kaynaklı tümörler toraksta ve medias-tinumda nadir olarak görülmekte ve rapor edilmektedirler. Biz burada, agresif fibromatozisin, toraks içi dokulardan kaynaklanan nadir bir formunu bildirmek istedik. Otuz altı yaşında bayan hasta hastanemize sol göğüs ağrısı ve sıkışma hissi ile başvurdu. Çekilen PA grafi ve toraks bilgisayarlı tomografisinde, sol toraks alt kısmını üçte iki oranında dolduran dev kitle görüldü. Bunun üzerine hastaya sol yedinci interkostal aralıktan yapılan torakotomi ile geniş rezeksiyon uygulandı. Tümör patolojisi 20x15x15 cm çapında agresif fibromatozis olarak geldi. Hasta 15 aydır takip altında ve kontrollerinde yinelenme görülmüdü.

**Anahtar sözcükler:** Agresif fibromatozis; desmoid tümör.

Aggressive fibromatosis is a rarely seen soft tissue tumor and originate principally from deep seated fascial or musculoaponeurotic structures.<sup>[1]</sup> Tumors of fibrous tissue origin (fibromatosis) in chest and mediastinum have been rarely reported in the literature.<sup>[1-9]</sup> They are characterized by the proliferation of fibroblasts with no cytological evidence of malignancy and are organized in the form of fasciae. Aggressive fibromatosis are considered low-grade malignant sarcomas. Locally invasive, they tend to recur increasing morbidity or even mortality. The cause is unknown

(trauma, hormonal factors, genetic anomaly).<sup>[2]</sup> Wide radical resection should be attempted whenever possible. In cases of recurrences, multimodality therapies should be considered.

### CASE REPORT

A case of an extra-abdominal desmoid tumor presenting as an intrathoracic tumor in a 36-year-old woman is reported. She was admitted to our hospital general surgery department with left chest wall pain and feeling of oppression in the left chest. On percussion, a dull

Presented at the 29th National Congress of the Turkish Respiratory Research Society, October 28-31, 2007, Fethiye, Turkey (29. Türkiye Solunum Araştırmaları Derneği Ulusal Kongresi'nde sunulmuştur, 28-31 Ekim 2007, Fethiye).

Correspondence (İletişim adresi): Dr. Yekta Altumur Karamustafaoğlu. Trakya Üniversitesi Tıp Fakültesi, Göğüs Cerrahi Anabilim Dalı, Kat:4, Balkan Yerleşkesi 22030, Edirne. Tel: 0284 - 235 59 36 Fax (Faks): 0284 - 235 59 36 e-mail (e-posta): altumurk@hotmail.com

© Trakya Üniversitesi Tıp Fakültesi Dergisi. Ekin Tıbbi Yayıncılık tarafından basılmıştır. Her hakkı saklıdır.

© Medical Journal of Trakya University. Published by Ekin Medical Publishing. All rights reserved.

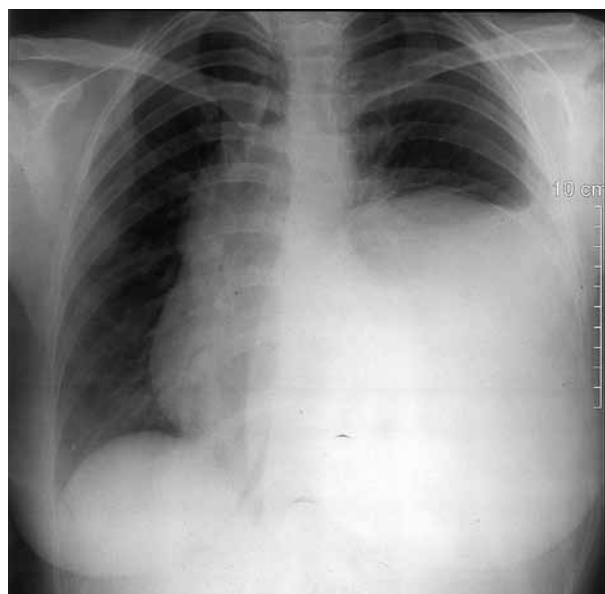


Fig. 1. X-ray showed large mass in the left lower zone.

sound was found in the left lower zone of the chest. Auscultation revealed normal cardiac sounds and normal breathing sounds on the right side and upper left side of the chest. Abdominal examination revealed no palpable masses or other abnormalities and abdominal computed tomography (CT) was normal. A chest X-ray revealed a large homogenous opacity filling two thirds of lower left thorax (Fig. 1). Computed tomography (CT) imaging showed a mass with a dimension of 20x15x15 cm, started at the level of thoracic sixth vertebra reaching the L1-L2 vertebra and specially in supradiaphragmatic level mediastinum invaded with tumor (Fig. 2). Fine needle biopsy had been performed by general surgeons had revealed diagnosis of mesenchymal tumor. Left thoracotomy was performed via seventh intercostal space. At the operation, huge extrapulmonary mass was seen protruding from eleventh

and twelfth rib extending to mediastinum posterolaterally. There were no adhesions and invasion to descending aorta and hilum. The mass was completely resected with the invaded eleventh and twelfth ribs and with adjacent partial diaphragm. Postoperative course was uneventful. All surgical margins were tumor free. The immunohistochemical examination showed that the cytoplasm of the tumor cells were strongly positive for vimentin, some tumor cells were positive for alpha-smooth muscle actin, but all tumor cells were negative for CD34. So these findings suggested intrathoracic extrapulmonary aggressive fibromatosis. Patient is well in 15 months follow-up.

### CONCLUSION

Aggressive fibromatosis is a rarely seen soft tissue tumor. According to Enzinger and Weiss,<sup>[3]</sup> fibromatosis can be divided into superficial and deep types. The deep type of fibromatosis is the one that would affect the mediastinum is extra-abdominal fibromatosis (extra-abdominal desmoid tumour). Desmoid tumors are uncommon fibromatous tumors arising from musculoaponeurotic tissue characterized by spindle cell fibroblast and myofibroblast proliferation. The cause is unknown. The radiographic findings of desmoids are variable. CT usually shows either a well-circumscribed or an ill-defined soft tissue density of variable attenuation when compared with muscle tissue. After the administration of contrasts, the attenuation may be higher than adjacent muscle tissue.<sup>[4]</sup> Desmoid tumors are considered benign because of their cytological features and because they don't give rise to metastases, but their biological behavior is that of a locally aggressive tumour. They do recur locally if they are not completely excised of which is not infrequent after surgical resection.<sup>[5,6]</sup> Fibromatosis like tumors could arise from pleura and constitute 5% of all pleural tumors.<sup>[9]</sup> Such tumors are usually solitary and multifocal tumors are not commonly reported. They should be treated by complete excision. Resection must be as radi-

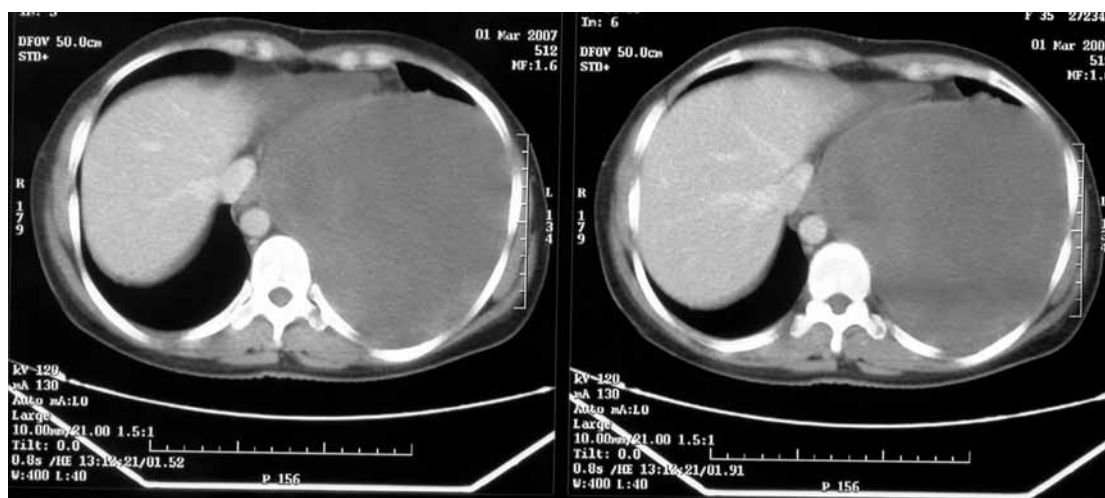


Fig. 2. Computerised tomography revealed large mass in the left thorax.

cal as possible. Partial resection of a desmoid tumour has been reported but the residual tumour was present at one year follow-up.<sup>[5,7]</sup> The follow-up of long term is necessary because it may recur. We performed surgical resection with wide free margin excision in our case with no recurrence during 15 months. Chemotherapy and hormonal treatment of non-resectable tumors has been described without convincing results and more data from clinical studies are needed.<sup>[8]</sup>

### REFERENCES

1. Posner MC, Shiu MH, Newsome JL, Hajdu SI, Gaynor JJ, Brennan MF. The desmoid tumor. Not a benign disease. *Arch Surg* 1989;124:191-6.
2. Giraudet-Le Quintrec JS, Minoui A, Frenaux E, Anract P, Fadel E, Missenard G, et al. Desmoid tumor of the thoracic wall. A case manifesting as painful stiffness of the shoulder. *Presse Med* 1998;27:1727-30. [Abstract]
3. Enzinger FM, Weiss Sw. Fibrohistiocytic tumors of intermediate malignancy. In: Enzinger FM, Weiss SW, eds. 3rd ed. St Louis: CV Mosby. 1995. p. 325-49.
4. Shields TW, Robinson PG. Mesenchymal tumors of the mediastinum. In: Shields TW, LoCicero J, Ponn RB, Rusch VW, editors. *General thoracic surgery*. Vol. 2, 6th ed. Philadelphia: Lippincott Williams and Wilkins; 2005. p. 2786-811.
5. Easter DW, Halasz NA. Recent trends in the management of desmoid tumors. Summary of 19 cases and review of the literature. *Ann Surg* 1989;210:765-9.
6. Reitamo JJ, Scheinin TM, Häyry P. The desmoid syndrome. New aspects in the cause, pathogenesis and treatment of the desmoid tumor. *Am J Surg* 1986;151:230-7.
7. Wilson RW, Gallateau-Salle F, Moran CA. Desmoid tumors of the pleura: a clinicopathologic mimic of localized fibrous tumor. *Mod Pathol* 1999;12:9-14.
8. Sørensen A, Keller JØ, Nielsen OS, Jensen OM. Aggressive fibromatosis. *Ugeskr Laeger* 2000;162:6676-8. [Abstract]
9. Vara Prasad RM, Thankachen R, Parihar B, Viyak S, Korula RJ. Mediastinal fibromatosis- A Case report. Abstract. *Ind J Thorac and Cardiovasc Surg* 2003;19:203.